

Circumscribed Pigmentations After Iron Injections—Treatment With Q-Switched Laser Systems

Christian Raulin, MD,^{1*} Saskia Werner, MD,² and Baerbel Greve, MD,¹

¹Laserklinik Karlsruhe, Germany

²Department of Dermatology, University Hospital of Heidelberg, Heidelberg, Germany

Background and Objective: Cutaneous brown discolorations in the area of injection can be a cosmetically bothersome side effect from a parenteral iron treatment, and have not responded to an effective therapy until now.

Study Design/Patients and Methods: We report retrospectively on five patients who were treated with the Q-switched ruby and/or Nd:YAG laser for circumscribed siderosis after intramuscular or intravenous iron injection.

Results: The number of required laser treatments was between 3 and 16. The clinical improvement after the first 2–4 sessions was the most impressive, especially after the application of the Nd:YAG laser. Hypopigmentation and scars did not develop. In one case hyperpigmentation appeared.

Conclusion: This study shows that there is an effective method of clearing persistent brown discolorations with few side effects after parenteral iron therapy, using Q-switched laser technology. *Lasers Surg. Med.* 28:456–460, 2001. © 2001 Wiley-Liss, Inc.

Key words: iron injections; Q-switched Nd:YAG laser; Q-switched ruby laser; siderosis

INTRODUCTION

Circumscribed grayish black-to-brown pigmentation after intramuscular injection of an iron preparation (mostly gluteal) can develop from the reflux of the injected solution through the injection site and the following distribution of the iron (Fe^{3+} -complex compounds; as stated by the Hausmann Company) in the skin [1–3]. Such pigmentations could also occur with iron solutions which are inadvertently injected paravenously. In one case, we have even observed a circumscribed brown pigmentation in the face after oral iron supplementation. These changes in skin color, which are rarely described in published works, appear days, and in many cases only weeks, after treatment and persist for at least 6–8 months up to several years [2,4]. The size of the lesions can vary from 1.0 cm to 8 cm. Furthermore, the localization does not necessarily have to be identical with the area of injection. The pigmentation can appear in neighboring areas of the skin by subcutaneous spreading. *Techniques* for the removal or bleaching of such aesthetically bothersome pigmentation have not been described in published works until now. A reference is made to spontaneous regression [2,3]. With the application of Q-switched laser systems (ruby,

Nd:YAG, alexandrite lasers) over the past few decades, the removal of cutaneous located pigment deposits has been made possible. Very good results have been achieved in the treatment of decorative and traumatic tattoos [5–8]. In the treatment of minocycline-induced hyperpigmentation, in which a *similar* pigment containing iron has been histologically detected, the Q-switched ruby and Nd:YAG lasers have proven to be safe and effective [9,10].

This study shows the efficacy of Q-switched ruby and Nd:YAG laser systems in the removal of cutaneous iron deposits.

MATERIALS AND METHODS

In this retrospective study, the data of 5 female patients whose cutaneous iron deposits were treated with Q-switched lasers from February 1997 to May 1999 were analyzed. The demographic data are listed in Table 1.

Two patients consented to biopsies before treatment. Unfortunately none consented to biopsies after treatment.

Histological results (Patient No. 2; right buttock. Fig 2): Under an epithelium of average thickness, numerous heavily pigment-laden macrophages appear in all dermal layers, extending to the border of the subcutis and especially numerous in the middle dermis, located perivascularly and periadnexally. The pigment is best demonstrated with Prussian-blue stain.

Histological results (Patient No. 4; left buttock): Flat epithelium. Few pigment phages in the corium area. These pigment phages store brownish pigment. This appears as hemosiderin in the iron coloring (Prussian-blue coloring).

The laser treatments were carried out with the Q-switched ruby laser (Lambda Photometrics Ltd; wavelength 694 nm; pulse length 25 nanoseconds; pulse diameter 2–4 mm; maximum energy density 40 J/cm²) and/or with the Q-switched Nd:YAG laser (Continuum Biomedical; wavelength 1064 nm; pulse length 5–7 nanoseconds; pulse diameter 2–6 mm; maximum energy density 12 J/cm²) in intervals of 4–8 weeks (Table 2). Only two patients were treated with the Q-switched Nd:YAG laser and only one

Correspondence to: Christian Raulin, MD, Laserklinik Karlsruhe, Kaiserstrasse 104, 76133 Karlsruhe, Germany
E-mail: info@laserklinik.de

Accepted 17 October 2000

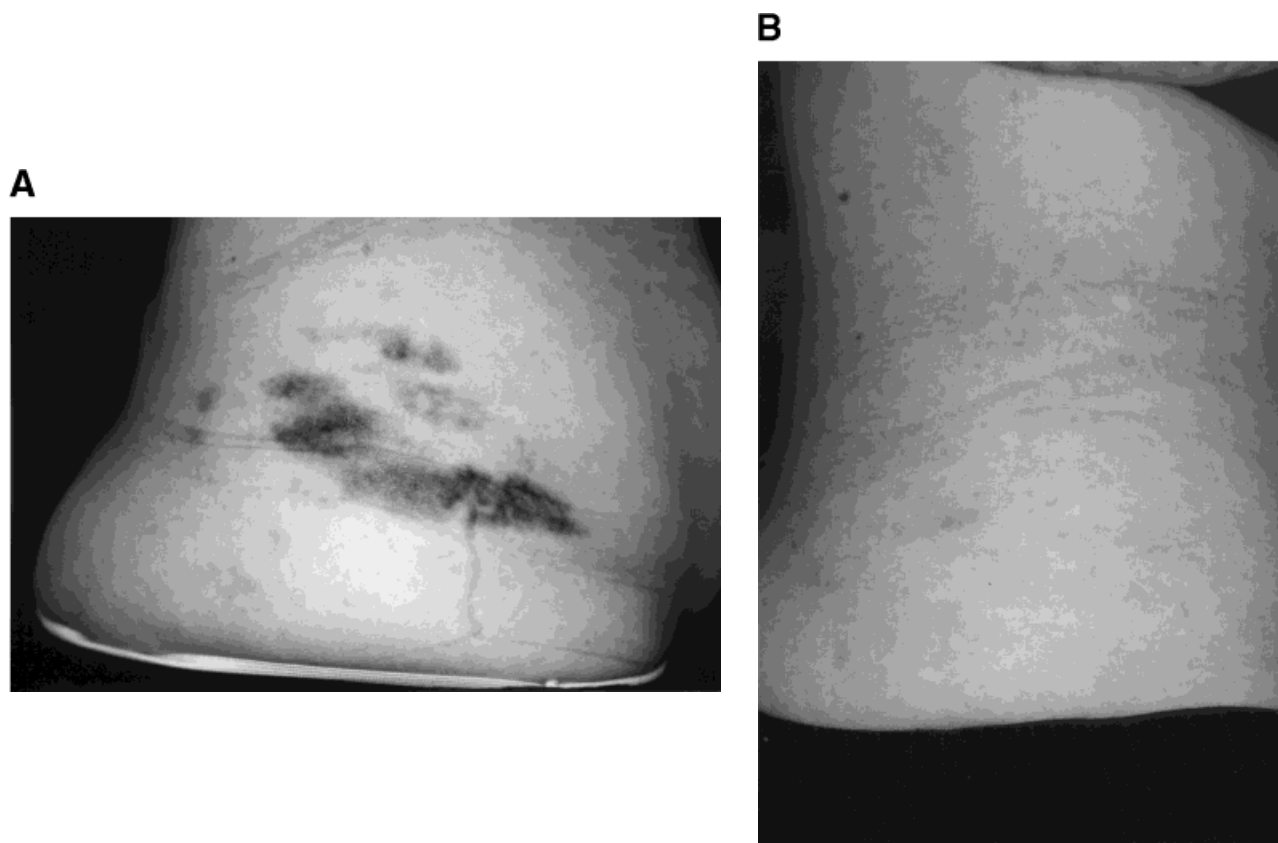


Fig. 1. (A) Circumscribed siderosis right-gluteal on a 31 year-old female patient (Pat) before therapy. (B) Visible lightning after seven sessions with the ruby laser and nine sessions with the Nd:YAG laser.

TABLE 1. Demographic data

No.	Age (years)	Localization	Size (cm ²)	i.m./i.v. ^a	Number of injections until appearance of siderosis	Persistence of siderosis (in months) at presentation	Iron preparation
1	49	Right buttock	14	i.m.	3	54	?
		Left buttock	15	i.m.	3		
2	31	Right buttock	24	i.m.	1	12	Ferric(III)-hydroxide-polymaltosis-complex
		Left buttock	18	i.m.	1		
3	24	Right buttock	5	i.m.	8	9	?
		Left buttock	2	i.m.	8		
4	58	Right buttock	5	i.m.	2	13	?
		Left buttock	30	i.m.	2		
5	36	Right forearm	4	i.v.	8	6	?
					(through indwelling cannula)		

^ai.m., intramuscular; i.v., intravenous.

TABLE II. Number of sessions and degree of clearance after therapy with the Q-switched ruby/Nd:YAG laser

Patient No.	Number of ruby laser treatments	Number of Nd:YAG laser treatments	Total	Degree of clearance	Reason for ending the therapy	Patient satisfaction
1	7	—	7	3	Patient's request	Yes
2	7	9	16	3	No further clearance	No
3	1	9	10	3	Patient's request	Yes
4	—	11	11	3	Changed health insurance companies	Yes
5	—	3	3	3	Patient's request	Yes

patient with the ruby laser (Nd:YAG lasers were not available at that time). A few patients had interruption in their treatments—some for several months—due to personal reasons.

In each laser session, all affected areas of skin were treated. Two patients were administered a topical anaesthetic (EMLA[®] cream, lidocaine–prilocaine mixture) 1–3 hours before the laser therapy **to minimize pain**. After each treatment, sulfadiazine ointment bandages (Flamazine[®]) were applied.

Before beginning and after ending the therapy, the areas of skin were photodocumented (Cannon EOS 100 camera; Agfa CTX 100 film). The degree of clearance was assessed according to the following scale: Rating 4, complete clearance; Rating 3, marked clearance; Rating 2, moderate clearance; Rating 1, nearly no clearance. Three independent doctors determined the degree of clearance by comparing the pre- and post-treatment photographs.

RESULTS

Number of Sessions and Clearance

Between three and 16 sessions were held per patient. None of the female patients had a complete clearance of the brownish grayish skin discolorations. However, visible lightening (Rating 3) could be achieved in all cases (Figs. 1, 3). The clinical improvement after the first 2–4 sessions was the most impressive. Further treatments brought only **minimal further** improvement. Four out of five treated patients were satisfied with the achieved results. The individual range of improvement and the number of laser sessions are listed in Table 2.

Applied Energy Densities

Energy densities between 6 and 40 J/cm² were used with the Q-switched ruby laser. With the Q-switched Nd:YAG laser, energy densities between 3.5 and 6.1 J/cm² (= maximum energy with a 3-mm handpiece) were used. The energy densities were continually increased from session to session.

Side Effects and Concomitant Side Effects

All patients had minor swelling directly after treatment. From the second to third day on after therapy, light crusting developed that persisted for 4–7 days. **Bleeding**

in the form of 1–2 mm macules, occurred in four patients, especially after Nd:YAG laser therapy. No blisters formed; Post-therapeutic infections were not observed. Three patients felt pain in the treated area of skin 2–3 days after laser therapy—regardless of the type of laser (also when EMLA[®] was used). Hypopigmentation did not occur. Hyperpigmentation was observed on one patient (siderosis on the right forearm; Nd:YAG laser therapy), which was still slightly present 14 months after the last treatment. No scarring occurred.

DISCUSSION

Deposition of metallic salts in the cutaneous connective tissue can result in persistent pigmentation, which is often difficult to treat. In addition to argyrosis (status post-therapy with substances containing silver), chrysiasis (after gold salt therapy) and exogenous ochronosis (from bleaching creams containing hydroquinone), siderosis as unintentional tattoo is also an exogenous dyschromia [11]. Due to the existing potential side effects from a parenteral iron therapy (among others, systematic reactions from i.v. injection, skin discolorations and tissue alterations from i.m. injection), an oral substitute should be used [12]. Indications for a parenteral iron therapy include disorders of malabsorption such as colitis ulcerosa, morning sickness, extreme loss of blood and patients' insufficient compliance with oral administration [1,2].

The brownish grayish discolorations that appear after intramuscular iron injections often have no distinct contours and are variable in their shades of color. Histologically, the stored iron in the Prussian-blue coloring shows up especially well. In all layers of the dermis, there are numerous perivascular and periadnexal (especially around the eccrine sweat glands) macrophages that are heavily iron pigment-laden (Fig. 2; see histological results). The deposits then reach the subcutis layers; they are consequently located up to 5–7 mm deep. Comparatively speaking, most pigment granules from professionally done, decorative tattoos are located in the upper dermis, in macrophages and fibroblasts, as was shown by Zelickson et al. [13] from biopsies of guinea pig skins that were tattooed by machine [13].

Q-switched laser systems, such as the ruby, Nd:YAG, and alexandrite lasers, have proven themselves effective

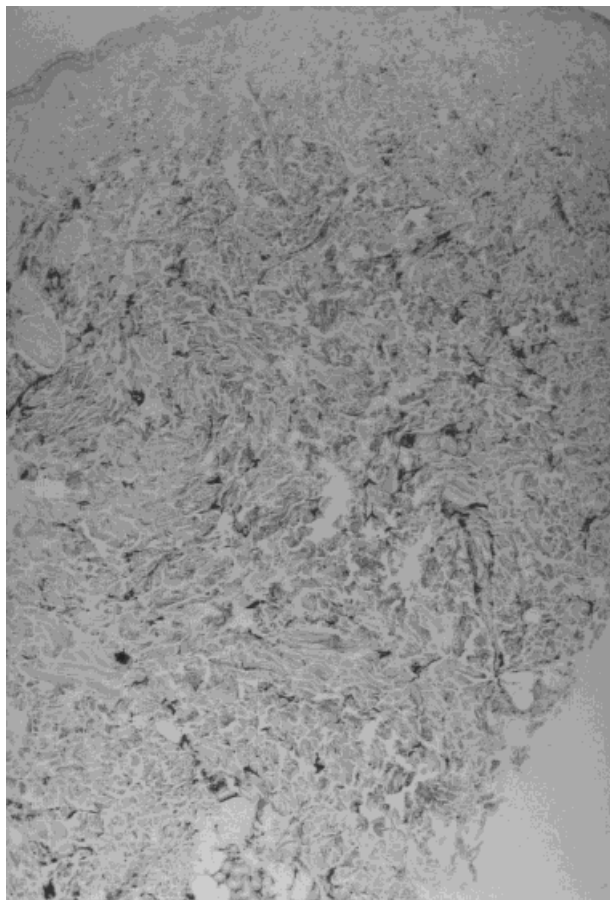
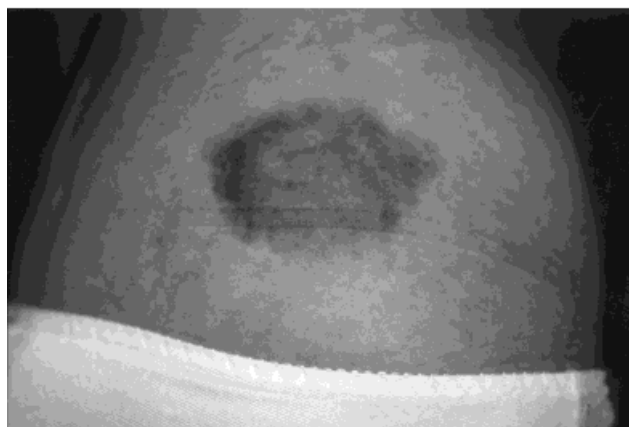

Fig. 2. Histological photograph to Fig. 1: Dermal iron deposits (Prussian-blue coloring).

in the removal of tattoos with the fewest possible side effects over the past 10 years. These lasers work according to the principle of selective photothermolysis, defined by Anderson and Parrish [14] in 1981. The target structures are pigment particles in the skin when the Q-switched lasers are used for tattoos. Due to the explosion-like heat development (>1000°C) after the laser impact, the most superficial pigment is transformed into gas and is dissolved in the extra-cellular fluid. Lower-lying pigment is fragmented into small particles, rephagocytized by macrophages and eliminated by the lymph fluid. A part of the pigment is also transepidermally removed with the crust [15,16]. In this manner, the tattoo gradually fades and eventually disappears. When the color particles lie very deep, in the lower dermis, they cannot be completely destroyed with the available Q-switched lasers and, color residue remains on the skin. The idea of treating circumscribed, cutaneous iron pigment deposits with laser systems arose from the above-mentioned proven therapy strategies for tattoos.

Considering our results, a visible lightening of the brown discolorations could be achieved in all cases.

A



B




Fig. 3. (A) Circumscribed siderosis right-gluteal on a 24-year-old female patient before therapy. (B) Visible lightening after one session with the ruby laser and nine sessions with the Nd:YAG laser.

However, a complete removal was not observed. This is probably caused by, as histologically proven, the fact that the iron pigment is pushed through the entire dermis to the border of the subcutis. Deep-lying iron cannot be reached by the laser and remains unchanged in the skin. The Q-switched Nd:YAG laser was often used on our patients (32 out of 47 laser sessions). Due to its longer wavelength (1064 nm), the infrared Nd:YAG laser is barely absorbed by melanin, is not scattered as widely by dermal collagen fibers and, therefore, penetrates deeper into the skin, as compared to the Q-switched ruby laser (694 nm; 1–2 mm) [17,18].

The first patient was treated solely with the Q-switched ruby laser because we purchased a Q-switched Nd:YAG laser after that treatment had finished. Due to the deeper penetration of Q-switched Nd:YAG laser and especially because of its faster rate of repetition (10 Hz; ruby approximately 1 Hz), we treated all other patients only with this laser system. The only way to clarify which laser type

demonstrates the greater efficacy would be to conduct a prospective comparative study.

The energy densities were continually increased from session to session due to the fact that the greater the density of the pigment, the more absorption occurs. High energy densities at the beginning of a circumscribed pigmentation treatment can therefore lead to unnecessary skin irritation.

In this study, a method with few side effects for clearing cosmetically bothersome skin discolorations after parenteral iron injections is described for the first time. Today, it is no longer necessary to wait for possible spontaneous regression [1–4]. Despite partially incomplete clearance, a high degree of satisfaction could be reached for our patients. Due to the low side effect rate and the efficacy, we recommend the above-mentioned laser therapy as the treatment method of choice for similar cases.

ACKNOWLEDGMENTS

We thank Professor W. Hartschuh, MD (University hospital Heidelberg) and A. Rütten, MD (Dermatohistopathological Institute Friedrichshafen) for their specialized consultation and support with regard to the histological findings and for providing the histological photographs.

REFERENCES

- Gartmann H, Linker U. Umschriebene Pigmentierungen nach intramuskulärer Injektion eines Eisenpräparates. *Dtsch Arztebl* 1972;69:2953–2954.
- Bork K. Lokalisierte kutane Siderose nach intramuskulären Eiseninjektionen. *Hautarzt* 1984;35:598–599.
- Suhonen RE, Helle MJ. Gluteal patches from intramuscular iron. *Eur J Dermatol* 1993;3:469–470.
- Doutre MS, Beylot-Barry M, Beylot C, Vergier B, Surleve-Bazeille JE. Gluteal pigmentation after intramuscular iron injections. *Dermatology* 1996;192:187–188.
- Raulin C, Emonds T. Entfernung von Schmutztätowierungen durch güetegeschaltete Laser Chirurg 1998;69:1270–1274.
- Raulin C, Schoenermark M, Greve B, Werner S. Q-switched ruby laser treatment of tattoos and benign pigmented skin lesions: a critical review. *Ann Plast Surg* 1998;41:555–565.
- Werner S, Drosner M, Raulin C. Entfernung von Tätowierungen mit dem güetegeschalteten Rubinlaser (694 nm) und dem güetegeschalteten Nd:YAG-Laser (532 und 1064 nm). Eine Retrospektivstudie. *Hautarzt* 1999;50:174–180.
- Alster TS. Q-switched alexandrite laser treatment (755 nm) of professional and amateur tattoos. *J Am Acad Dermatol* 1996;33:69–73.
- Greve B, Schoenermark MP, Raulin C. Minocycline-induced hyperpigmentation: treatment with the Q-switched Nd:YAG laser. *Lasers Surg Med* 1998;22:223–227.
- Tsao H, Busam K, Barnhill RL. Treatment of minocycline-induced hyperpigmentation with the Q-switched ruby laser. *Arch Dermatol* 1996;132:1250–1251.
- Rook A, Wilkinson DS, Ebling FJG, Champion RH, Burton RH, (editors). *Textbook of Dermatology*. 4th edn., Vol. 1. Oxford: Blackwell Scientific Publications, 1988: p. 863–865.
- Kumpf VJ. Parenteral iron supplementation. *Nutr Clin Pract* 1996;11:139–146.
- Zelickson BD, Mehregan DA, Zarrin AA, Coles C, Hartwig P, Olson S, Leaf-Davis J. Clinical, histologic, and ultrastructural evaluation of tattoos treated with three laser systems. *Lasers Surg Med* 1994;15:364–372.
- Anderson RR, Parrish JA. The optics of human skin. *J Invest Dermatol* 1981;77:13–19.
- Ferguson JE, Andrew SM, Jones CJP, August PJ. The Q-switched neodymium:YAG laser and tattoos: a microscopic analysis of laser-tattoo interactions. *Br J Dermatol* 1997;137:405–410.
- Taylor CR, Anderson RR, Gange RW, Michaud NA, Flotte TJ. Light and electron microscopic analysis of tattoos treated by Q-switched ruby laser. *J Invest Dermatol* 1991;97:131–136.
- Anderson RR, Margolis RJ, Watanabe S, Flotte T, Hruza GJ, Dover JS. Selective photothermolysis of cutaneous pigmentation by Q-switched Nd:YAG laser pulses at 1064, 532, and 355 nm. *J Invest Dermatol* 1989;93:28–32.
- Hruza GJ, Dover JS, Flotte TJ, Goetschkes M, Watanabe S, Anderson RR. Q-switched ruby laser irradiation of normal human skin. *Arch Dermatol* 1991;127:1799–1805.