

Fractional, Non-Ablative Laser Therapy for the Treatment of Striae Distensae

Francesca de Angelis, MD – Plastic Surgeon, Specialists in Plastic Surgery, Naples, Italy

Larissa Kolesnikova, MD – Dermatologist, Fonte del Benessere SRL, Milan, Italy

Overview

Fractional, non-ablative laser therapy has the potential to effectively treat striae on multiple fronts: coagulation of microvasculature resolves violaceous erythema, and resurfacing of surrounding tissue smoothes skin texture and reduces hyper- and hypo-pigmentation. This report describes our treatment experiences and clinical outcomes using a 1540 nm erbium glass laser (the FDA-cleared Lux1540™ Handpiece, Palomar Medical Technologies, Inc., Burlington, MA) to treat striae. Observed results include significant improvements in the pigmentation, textural irregularities and overall appearance of both striae rubra and striae alba.

Introduction

Striae distensae, or stretch marks, are linear scars in the dermis which arise from rapid stretching of the skin over weakened connective tissue (1). Histology of mature striae reveals thin and retracted collagen and elastin fibers resulting in a lack of supporting material and an atrophied epidermis (2). Striae may result from a number of causes, including, but not limited to, rapid changes in weight, adolescent growth spurts, corticosteroid use or Cushing Syndrome, and generally appear on the buttocks, thighs, knees, calves, or lumbosacral areas (3-5). In addition, approximately 90% of all pregnant women develop stretch marks either on their breasts and/or abdomen by the third trimester (6). The three maturation stages of striae include the acute stage (striae rubra) characterized by raised, erythematous striae, the sub-acute stage characterized by purpuric striae, and the chronic stage (striae alba), characterized by white or hypo-pigmented, atrophied striae (7).

Currently, there is no treatment which consistently improves the appearance of striae and is safe for all skin types (8,9). Studies using topical tretinoin resulted in some improvements, but efficacy was limited to only early, active striae (10,11). A combination treatment using sand abrasion and 15% trichloroacetic acid has

demonstrated efficacy in the treatment of all types of striae; however, there is a learning curve for physicians using this open wound technique, and a positive outcome is dependent upon the subject's strict adherence to post-wound care instructions (12). Additional drawbacks include the significant downtime, up to a week for large areas, and the increased risk of post-inflammatory hyperpigmentation (PIH) for subjects with darker skin types, e.g., skin types V and VI (12).

Treatments with either UVB light therapy or the XeCL 308 nm excimer laser yielded only transient results with study authors recommending that subjects receive additional treatments every one to four months to maintain benefits (2,13). Between two small clinical studies examining the use of intense-pulsed light for striae, one reported positive histological changes that were unmatched by clinical and subject evaluations and the other reported PIH (8,14). Currently, the most common laser treatment for striae is with the 585 nm pulsed-dye-laser (PDL) (9) although its use has also been associated with PIH (1,15-17). In a comparison study with the 585 nm PDL and the short-pulsed CO₂ laser, persistent erythema was observed in a subject with type IV skin and marked PIH in a subject with type VI skin (18). Any observed improvements in the appearance of striae are thought to result from neocollagenesis in the extracellular matrix as documented by the Jimenez study which conducted collagen biochemical analysis on a subset of treated and non-treated regions (9,15,18).

Other types of lasers used to treat striae include the 1450 nm mid-infrared diode laser and the 1550 nm erbium-doped fractional laser. The one study examining the efficacy of the 1450 nm laser in Asian skin (Fitzpatrick Skin Types IV-VI) observed no noticeable improvement two months after treatment and PIH was observed in 64% of subjects (19). Studies with the fractional 1550 nm laser have been linked with more positive outcomes initially, but with questionable sustainability. In a small study by

Kim et al., subjects with skin types ranging from II-IV were treated with the 1550 nm erbium-doped fractional laser (7). Results showed increased production of collagen and elastin but only transient restoration of pigmentation (7). The Stotland study observed less than 50% overall improvement in 63% of its subjects and less than 25% improvement in dyschromia at three months post-treatment (20). Katz et al., observed greater improvement in two adolescent females with immature striae (aged: three months, ten months) following a course of three to five treatments spaced at four week intervals (21). Finally, the recent Bak study reported 27% of their subjects exhibited “good to excellent” improvement along with the commonly reported side effects of erythema, crusting and PIH (22). Interestingly, this study observed greater and longer lasting improvements for striae alba than striae rubra.

The results presented in this brief report describe the use of another fractional erbium glass laser (Lux1540™) to treat striae in 27 subjects with skin types ranging from II-IV. The Lux1540 is currently the only fractional laser cleared by the FDA to treat striae in the United States. Advantages of using fractional photothermolysis over PDL or other non-fractional lasers include the superior depth of coagulated microcolumns that are surrounded by untreated tissue to facilitate expedited and controlled healing. Another important benefit of fractional non-ablative treatment is the turnover of the basal layer of the epidermis which addresses dyspigmentary aspects of hyper- and hypo-pigmentation (23). In addition, fractional non-ablative treatments are well tolerated with minimal side effects, pain and downtime. Ideally, effective treatment of scar tissue should extend through the depth of the dermis and deliver consistent, long lasting improvements. In this study we found consistent improvement of striae following treatment with the Lux1540. The high selectivity of the 1540 nm wavelength for water and not melanin within the skin means that subjects with darker skin types (IV-VI) are at a reduced risk for blistering or scarring compared to treatment with the 585 nm PDL, intense pulsed light, or short-pulsed CO₂ (1,8,15,17,18). Our clinical data strongly supports the use of the Lux1540 for the treatment of striae distensae.

Treatment Protocol for Striae

Histology Profile

To establish appropriate treatment settings for our clinical study and to understand the range of coagulative depth achieved with the Lux1540, histological analyses were performed using an ex vivo Yucatan pig abdominal skin model. Visualization of thermally coagulated columns was achieved with Hematoxylin and Eosin (H&E) stain and cross-polarized light. Using energy settings of 52 mJ/mb, close to the clinical treatment range, we created micro-columns of coagulated tissue approximately 620 μm deep (not shown). Increasing the energy to 70 mJ/mb yielded even deeper coagulation columns of 720 μm (Fig. 1A-B).

With the Lux1540, practitioners can tailor their treatment parameters depending on the skin type, maturation stage, depth, and pigmentation of the striae. Using interchangeable optics, practitioners can select the 10 mm tip (100 microbeam (mb)/cm² density) to deliver higher energy settings for deeper striae and the 15 mm tip (320 mb/cm² density) to deliver lower energy, higher density settings for more superficial striae with pigmentation. In this clinical study, striae were treated with a range of energy from 34-50 mJ/mb and two to five passes of overlapping pulses per treatment for a total coverage of 600 mb/cm² to 1200 mb/cm². The dramatic clinical improvements observed may be due in part to the treatment of a region wider than the striae (deeper depths, wider expanse), thus allowing for more extensive removal and replacement of scar tissue with new, normalized tissue.

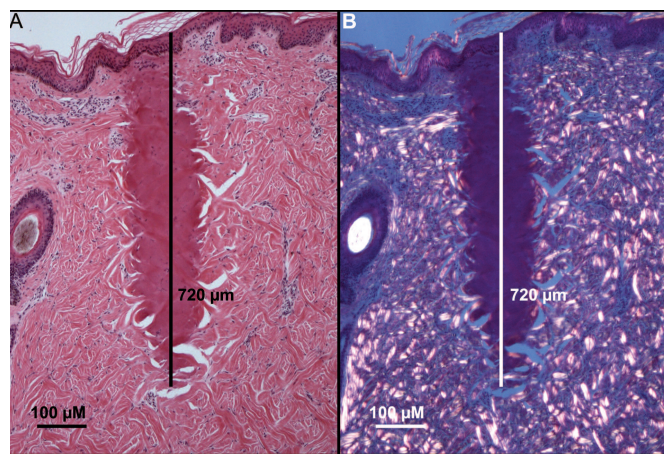


Figure 1. Ex vivo Yucatan Pig Histology Showing Depth of Coagulation. A) H&E stain reveals a coagulation column of 720 μm depth with 70 mJ/mb treatment. B) Cross-polarized light allows for greater visualization of the micro-columns of coagulated tissue.

Results

Clinical Observations

Efficacy data collected from our clinical subjects demonstrate the ability of the Lux1540 to treat a range of striae in varying degrees of maturation, from rubra to alba. Subjects tolerated the treatments well with only a minority of subjects requiring ice during treatment. Immediate side effects were limited to transient edema and transient erythema for all subjects with the addition of prolonged mild PIH for a few darker-skinned subjects. All side effects were resolved by our last follow up with all subjects. Two independent physicians assessed the 25 subjects who completed the study for improvement in the appearance of their striae. As shown in Table 1, the first physician observed 50% or greater improvement in all subjects (25/25) and 75% improvement in 24% of subjects (6/25). The second physician observed 50% or greater improvement in 96% of subjects (24/25) and 75% improvement in 8% of subjects (2/25).

Independent Investigator	% of Subjects with Degree of Improvement					
	0%	25%	50%	75%	100%	Mean
#1	0%	0%	76%	24%	0%	56%
#2	0%	4%	88%	8%	0%	51%

Table 1. Investigator-assessed improvement performed by two independent physicians.

Perhaps even more important, all of our treated subjects reported improvements of 50-100% in the appearance of their striae and all were satisfied with their results. Some examples of the significant improvements observed in both striae rubra and striae alba with a range of ages (8 months to 19 years) following treatment with the Lux1540 are shown in Figures 2-5.

Figure 2 shows a female subject with 19 year-old bilateral vertical striae on her lower abdomen prior to treatment (Fig. 2A, see right panel for enlargement of striae). Treatments with the Lux1540 were performed on one side, allowing for direct comparison to untreated striae (control) on the other side for efficacy evaluations. After four treatments with three passes, compared to the untreated striae on the subject's right side, the striae on the left blended almost seamlessly with nearby normal skin. Specifically, the hyper-pigmentation and textural irregularities of the striae appeared significantly improved (compare areas within dotted circle in Fig. 2A and 2B).

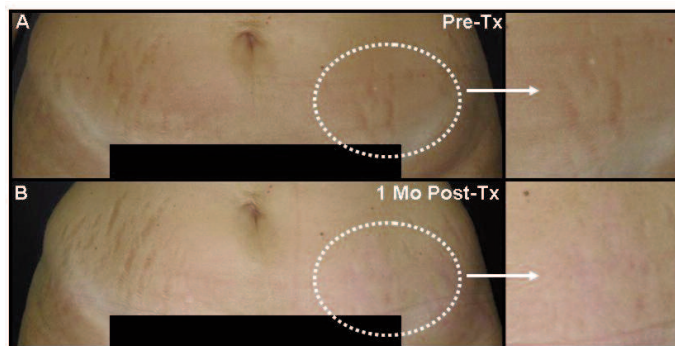


Figure 2. Proficiency of Lux1540 in Treating Abdominal Striae. A) Pre-treatment, the subject's striae appeared hyper-pigmented and depressed (within dotted circle) compared to the untreated striae on the subject's right side. C) Post-treatment, the treated area (compare magnified images within dotted circles) appeared softer and the hyper-pigmentation was resolved. Arrows point to enlargements of treated areas.

The subject in Figure 3 is a 43 year old female (Fitzpatrick Skin Type IV) with 17 year-old horizontal striae alba on her lower abdomen as a result of pregnancy (Fig. 3A). This subject received three, three-pass treatments with the Lux1540 using the 15 mm tip. Seven months after the last treatment, despite the advanced maturation stage of the subject's striae, the Lux1540 treatment reduced the hypopigmentation and improved the overall appearance of the striae.

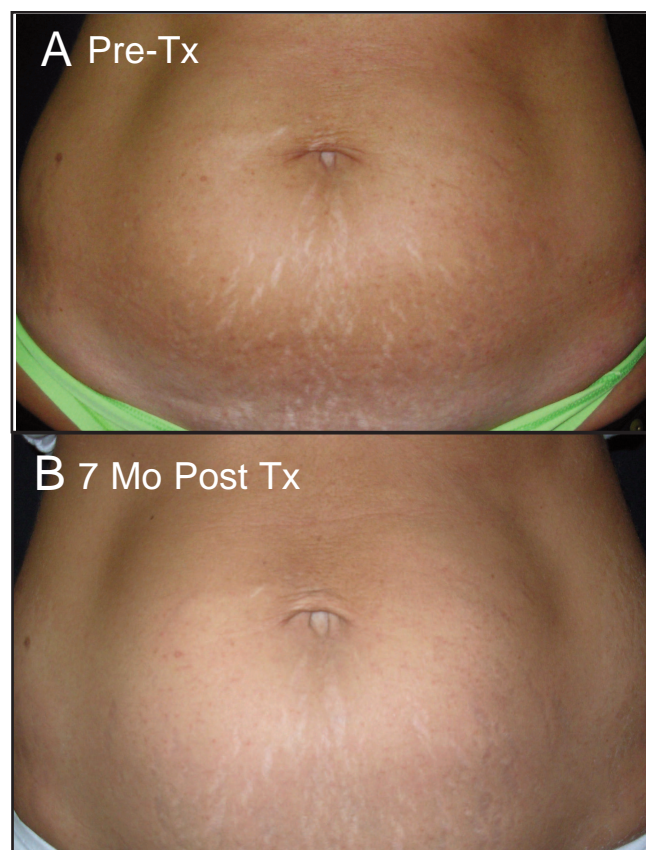


Figure 3. Re-pigmentation of Lower Abdominal Striae Post Lux1540 Treatment. A) Prior to treatment, hypopigmented striae spanned the subject's lower abdomen. B) Post-treatment, textural irregularities were softened and hypopigmentation was reduced.

Figure 4 shows an example of a female with seven year-old horizontal striae alba on her breast, a common side effect of pregnancy. Prior to treatment with the Lux1540, the hypopigmented striae spanned the height of the breast (Fig. 4A, area within dotted half-circle). After four treatments with three passes, the subject's striae were markedly improved with near-complete re-pigmentation and a return of natural skin appearance (Fig. 4B).




Figure 4. Global Improvement of Striae in the Breast. A) Subject had numerous striae on the breast (encapsulated within blue dotted line) before a Lux1540 treatment. B) One month after treatment, striae were visibly reduced.

In another study run by Dr. Sean Doherty and Dr. Brooke Seckel, similar improvements were shown for a subject with stria rubra. Using comparable treatment settings to ours, their results corroborate our findings and demonstrate the ability of the Lux1540 to successfully treat striae rubra. The eight month old, pregnancy-induced striae rubra was treated with three passes with the Lux1540 using the 15 mm tip. Post-treatment, the textural irregularities and erythematous appearance of the striae were significantly reduced contributing to a much smoother transition from scar tissue to normal surrounding skin.

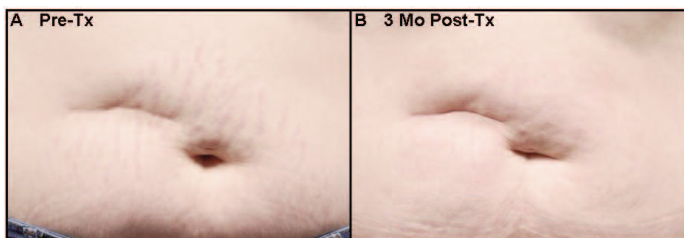


Figure 5. Significant Improvement of Striae Rubra. A) Subject had numerous periumbilical striae rubra. B) Three months after three treatments, the striae were barely visible. *Photos courtesy of Dr. Sean Doherty and*

Dr. Brooke Seckel, an employee and the Medical Director of Palomar Medical Technologies, Inc., respectively.

Discussion

Previous treatments for striae distensae have been restricted by their limited efficacy, inconsistency across subjects and inability to deliver lasting results. Our testing with the Lux1540 in 27 subjects with a broad range of striae varying in both anatomical location and maturation, resulted in significant improvements in textural irregularities as well as re-pigmentation of striae alba and reduction of erythematous striae rubra. An important predictor of any treatment's success is subject satisfaction. All of our treated subjects felt their striae had improved 50-100% and were extremely satisfied with the improved appearance of their striae. Corroborating these high satisfaction rates were two independent investigator assessments in which 100% and 96% of treated striae were assessed as having improved 50% or more. In contrast to other published results, we have now followed our subjects for up to 15 months and observed no recurrence of striae. Anecdotally, we were unable to recognize striae in three subjects six months after treatment.

One of the unique features of the treatment which significantly reduces the risk of PIH is the Lux1540's user-selectable tips enabling practitioners to tweak treatment settings depending on the subject's skin type. Reduced risk for PIH with the Lux1540 can also be attributed to the selectivity of the wavelength for water, not melanin. Fractional delivery of microcolumns of coagulation can result in minimal side effects like edema and erythema, little to no downtime, and minimal pain for subjects. Ex vivo Yucatan pig histology illustrates the capability of the Lux1540 to create fractional microcolumns of coagulated tissue as deep as 720 μm following treatment at 70 mJ/mb. With energy settings of 52 mJ/mb, close to the clinical treatment range, the fractional microcolumns are approximately 620 μm in depth. Our efficacy data demonstrate the ability of the Lux1540 to normalize hyper-pigmented striae and to re-pigment striae alba due to the removal and replacement of the coagulated microcolumns of tissue with new tissue. The clinical photos shown here demonstrate the superior ability of the Lux1540 in treating striae on various anatomical locations, including the abdomen and breast. In addition to the reduced side effects and downtime, Lux1540 treatments is the only FDA-cleared fractional laser treatment associated with significant improvements in the appearance and pigmentation of striae.

Conclusion

Fractional photothermolysis with the Lux1540 dramatically improves a wide range of striae, regardless of the depth, pigmentation abnormalities, anatomical location, and age of the striae. The limited side effects, long-lasting results and high subject satisfaction make this a valuable and practical addition to our practices.

References

1. McDaniel DH. Laser therapy of stretch marks. *Dermatol Clin* 2002; 20(1):67-76, viii.
2. Goldberg DJ, Marmur ES, Schmults C, Hussain M, Phelps R. Histologic and ultrastructural analysis of ultraviolet B laser and light source treatment of leukoderma in striae distensae. *Dermatol Surg* 2005; 31(4):385-387.
3. Zheng P, Lavker RM, Kligman AM. Anatomy of striae. *Br J Dermatol* 1985; 112(2):185-193.
4. Nieman LK, Ilias I. Evaluation and treatment of Cushing's syndrome. *Am J Med* 2005; 118(12):1340-1346.
5. Cho S, Park ES, Lee DH, Li K, Chung JH. Clinical features and risk factors for striae distensae in Korean adolescents. *J Eur Acad Dermatol Venereol* 2006; 20(9):1108-1113.
6. Tunzi M, Gray GR. Common skin conditions during pregnancy. *Am Fam Physician* 2007; 75(2):211-218.
7. Kim BJ, Lee DH, Kim MN, Song KY, Cho WI, Lee CK, Kim JY, Kwon OS. Fractional photothermolysis for the treatment of striae distensae in asian skin. *Am J Clin Dermatol* 2008; 9(1):33-37.
8. Hernandez-Perez E, Colombo-Charrier E, Valencia-Ibieta E. Intense pulsed light in the treatment of striae distensae. *Dermatol Surg* 2002; 28(12):1124-1130.
9. Elsaie ML, Baumann LS, Elsaie LT. Striae distensae (stretch marks) and different modalities of therapy: an update. *Dermatol Surg* 2009; 35(4):563-573.
10. Rangel O, Arias I, Garcia E, Lopez-Padilla S. Topical tretinoin 0.1% for pregnancy-related abdominal striae: an open-label, multicenter, prospective study. *Adv Ther* 2001; 18(4):181-186.
11. Kang S, Kim KJ, Griffiths CE, Wong TY, Talwar HS, Fisher GJ, Gordon D, Hamilton TA, Ellis CN, Voorhees JJ. Topical tretinoin (retinoic acid) improves early stretch marks. *Arch Dermatol* 1996; 132(5):519-526.
12. Adatto MA, Deprez P. Striae treated by a novel combination treatment--sand abrasion and a patent mixture containing 15% trichloroacetic acid followed by 6-24 hrs of a patent cream under plastic occlusion. *J Cosmet Dermatol* 2003; 2(2):61-67.
13. Alexiades-Armenakas MR, Bernstein LJ, Friedman PM, Geronemus RG. The safety and efficacy of the 308-nm excimer laser for pigment correction of hypopigmented scars and striae alba. *Arch Dermatol* 2004; 140(8):955-960.
14. Trelles MA, Levy JL, Ghersetich I. Effects Achieved on Stretch Marks by a Nonfractional Broadband Infrared Light System Treatment. *Aesthetic Plast Surg* 2008.
15. Jimenez GP, Flores F, Berman B, Gunja-Smith Z. Treatment of striae rubra and striae alba with the 585-nm pulsed-dye laser. *Dermatol Surg* 2003; 29(4):362-365.
16. McDaniel DH, Ash K, Zukowski M. Treatment of stretch marks with the 585-nm flashlamp-pumped pulsed dye laser. *Dermatol Surg* 1996; 22(4):332-337.
17. Suh DH, Chang KY, Son HC, Ryu JH, Lee SJ, Song KY. Radiofrequency and 585-nm pulsed dye laser treatment of striae distensae: a report of 37 Asian patients. *Dermatol Surg* 2007; 33(1):29-34.
18. Nouri K, Romagosa R, Chartier T, Bowes L, Spencer JM. Comparison of the 585 nm pulse dye laser and the short pulsed CO2 laser in the treatment of striae distensae in skin types IV and VI. *Dermatol Surg* 1999; 25(5):368-370.
19. Tay YK, Kwok C, Tan E. Non-ablative 1,450-nm diode laser treatment of striae distensae. *Lasers Surg Med* 2006; 38(3):196-199.
20. Stotland M, Chapas AM, Brightman L, Sukal S, Hale E, Karen J, Bernstein L, Geronemus RG. The safety and efficacy of fractional photothermolysis for the correction of striae distensae. *J Drugs Dermatol* 2008; (9):857-861.
21. Katz TM, Goldberg LH, Friedman PM. Nonablative fractional photothermolysis for the treatment of striae rubra. *Dermatol Surg* 2009; 35(9):1430-1433.
22. Bak H, Kim BJ, Lee WJ, Bang JS, Lee SY, Choi JH, Chang SE. Treatment of striae distensae with fractional photothermolysis. *Dermatol Surg* 2009; 35(8):1215-1220.
23. Hantash BM, Bedi VP, Sudireddy V, Struck SK, Herron GS, Chan KF. Laser-induced transepidermal elimination of dermal content by fractional photothermolysis. *J Biomed Opt* 2006; 11(4):041115.