

Fractional Photothermolysis Laser Treatment of Male Pattern Hair Loss

WON-SERK KIM, MD,* HYE IN LEE, MD,[†] JIN WOONG LEE, MD,[†] YUN YOUNG LIM, MD,[†]
SEUNG JAE LEE, MD,* BEOM JOON KIM, MD, PhD,[†] MYEUNG NAM KIM, MD,[†] KYE YONG SONG, MD,[‡]
AND WON SERK PARK, PHD[§]

BACKGROUND Various trials have been conducted on the management of male pattern hair loss (MPHL). A variety of laser and light sources have been used for the treatment of MPHL.

OBJECTIVE To understand the effects of a 1,550-nm fractional erbium-glass laser on the hair cycle in an alopecia mouse model and to study the clinical effects of the same laser used as treatment for MPHL.

MATERIALS AND METHODS Irradiation was applied to the shaved skin of C3H/HeN mice using various energy and density settings and varied irradiation intervals. In a clinical pilot study involving human subjects, 20 participants were treated over five sessions at 2-week intervals. A fractional photothermolysis laser was used at the energy of 5 mJ and a total density of 300 spots/cm².

RESULTS In the animal study, the hair stimulation effects were dependent upon the energy level, density, and irradiation interval. The anagen conversion of hair and the increase in Wnt 5a, β -catenin signals were observed. In the human pilot study, incremental improvements in hair density and growth rate were observed.

CONCLUSIONS This pilot study showed that a 1,550-nm fractional erbium-glass laser might induce hair growth, but more intensive studies are required to clarify the clinical applications of this treatment.

The authors have indicated no significant interest with commercial supporters.

Male pattern hair loss (MPHL) affects a large percentage of the male population. Various trials have been conducted for the management of this condition. Safe and effective medications have been available for the treatment of MPHL for several decades, with topical minoxidil and oral finasteride remaining the best agents for the treatment of hair loss.¹ Hair transplant surgery also remains an important option for people who do not have success with medical therapies. Personal preferences and a person's budget and lifestyle may play an important role in determining the best treatment option.

There continues to be interest in the potential roles of light and laser treatments for hair loss.² A number of products using low-energy light beams have been

marketed for the promotion of hair growth. Only one such device, the HairMax LaserComb (Lexington International, LLC, Boca Raton, FL), has obtained Food and Drug Administration approval for use.³ The mechanism of action of low-level light therapy (LLLT) is not known, and evidence regarding the mechanism remains relatively nonscientific. A variety of laser and light sources have been tested for the treatment of MPHL, including the excimer laser, the helium-neon laser, and psoralen plus ultraviolet A light. Some success has been reported with these therapies. Although the link between laser treatment and hair growth is not clear, and the exact mechanism of action in hair regrowth is unknown, there is evidence to support the idea that laser irradiation might have potential for the treatment of alopecia.

*Department of Dermatology, Kangbuk Samsung Hospital, Sungkyunkwan University School of Medicine, Seoul, Korea; Department of [†]Dermatology and [†]Pathology, College of Medicine, Chung-Ang University, Seoul, Korea; [§]Amore Pacific R&D Center, Seoul, Korea

The paradoxical hair growth seen after laser hair removal is a clinical example of photo-induced hair growth.⁴⁻⁷ It has been observed that hair growth may follow the induction of some level of wound healing, even though the mechanism for this is not known.⁸ These observations led us to question the type of laser that is most suitable for proper wounding and hair regrowth. The objective of this study was to determine the effects of a 1,550-nm fractional erbium-glass laser on the hair cycle in an alopecia mouse model. Additionally, through half-split controlled human trials, we assessed the effects of fractional photothermolysis at a 1,550-nm wavelength for hair regrowth in MPHL.

Materials and Methods

Animal Study

Materials

Animals: C3H/HeN mice (Orient Bio, Sungnam, Korea) were used in the animal experiments. The hair on the backs of 7-week-old mice was shaved with a clipper to study induced hair regrowth. Hair follicles were synchronously matched during the telogen stage.

Devices: Irradiation was applied to the shaved skin of the C3H/HeN mice using a 1,550-nm fractional erbium-glass laser (Mosaic, Lutronic, Seoul, Korea) at various energies, densities, and irradiation intervals.

Study Design

Study 1: Laser irradiation using various energy levels and densities: Six 7-week-old C3H/HeN mice whose hair was in the telogen stage were irradiated at various energy levels. The irradiation energy levels were 7 mJ for mice 1 and 2, 10 mJ for mice 3 and 4, and 15 mJ for mice 5 and 6. As indicated by the arrow in Figure 1A, each mouse was irradiated with five different densities (left upper, 300 spot/cm²; left lower, 600 spot/cm²; right upper, 1,000 spot/cm²; right lower, 1,500 spot/cm²; upper center, 2,000 spot/cm²).

Study 2: Laser irradiation at various intervals: Six 7-week-old C3H/HeN mice whose hair was in the telogen stage were irradiated at various intervals. Mice 1 and 2 were irradiated every 4 weeks, mice 3 and 4 every 2 weeks, and mice 5 and 6 every week. All six mice were irradiated at 7 mJ with an 800-spot/cm² density on the left side of the back and at 7 mJ with a 1,500-spot/cm² density on the right side of the back.

Histopathologic studies: Skin samples were obtained from the irradiated mice and analyzed for hair changes.

Molecular studies: Skin samples were obtained from the irradiated mice. Molecular signals and growth factors known to be associated with the hair cycle were analyzed.

Pilot Study of MPHL in Humans

Participant Profiles: Twenty Korean men aged 28 to 51 (mean age 40.7) with MPHL were enrolled in this pilot study. None had previously been treated for hair loss. The Norwood stages of hair loss were evaluated as stage III for seven participants, stage IV for nine participants, and stage V for four participants. Written informed consent for laser treatment and skin sampling was obtained from all volunteers.

Treatment Protocols: This study was a half-split study. The right side of the frontal scalp was irradiated with the 1,550-nm fractional photothermolysis laser in the static operating mode, and the left side of the scalp was left untreated as a control. No anesthesia was administered. Each participant received five treatment sessions administered at 2-week intervals. Each treatment was administered to the right scalp with an energy of 5 mJ and a total density of 300 spots/cm² (low energy and high density). Air cooling was applied for 5 minutes after the laser treatment. Shampooing, warm baths, and hard physical exercise were prohibited for 6 hours after the laser treatment. Application of topical agents

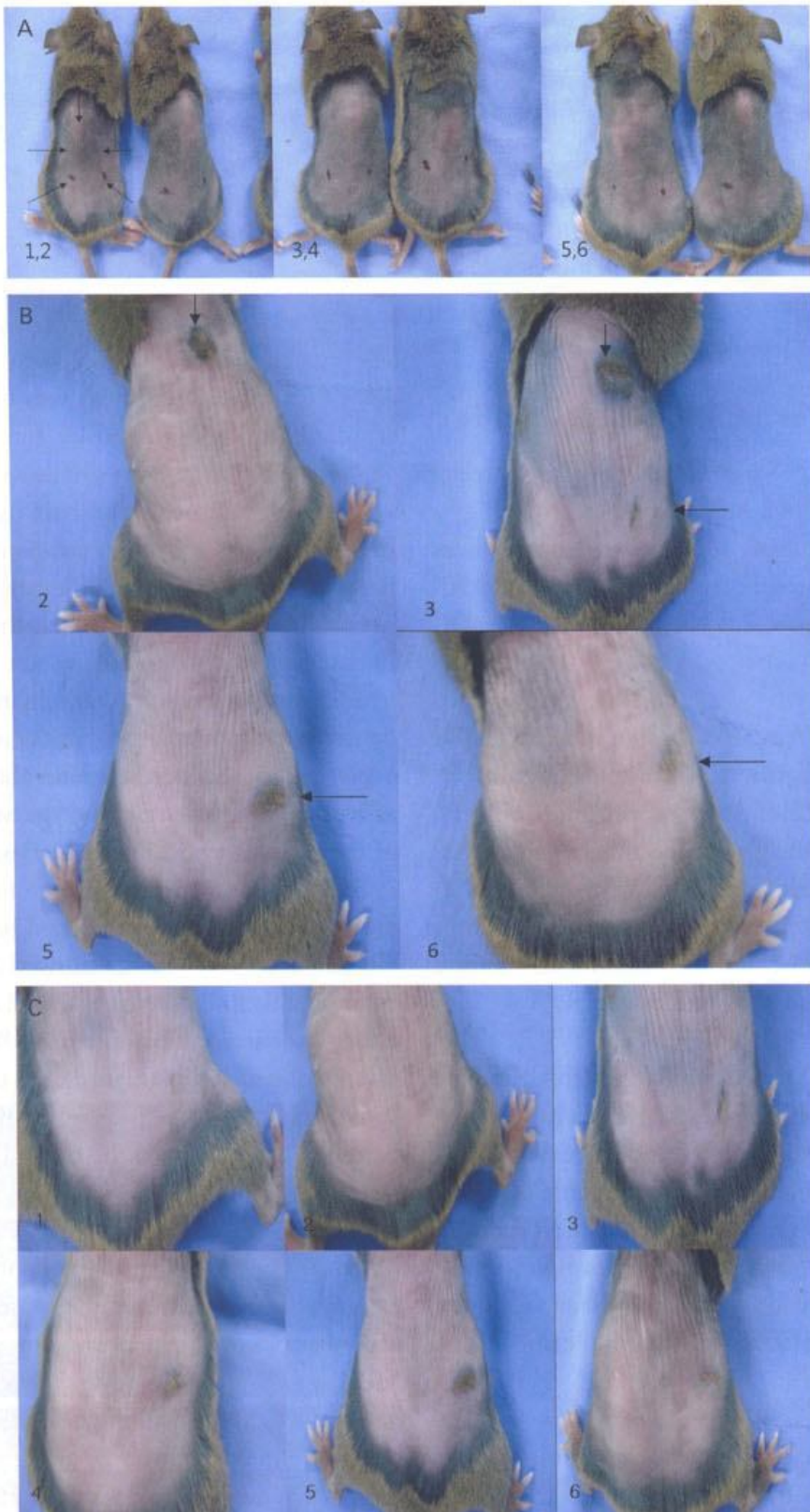


Figure 1. (A) Six 7-week-old C3H/HeN mice whose hair was in the telogen stage were irradiated with various energy levels (7 mJ for mice 1 and 2, 10 mJ for mice 3 and 4, and 15 mJ for mice 5 and 6). Each mouse was irradiated at five different densities, as indicated by the arrow (left upper, 300 spot/cm²; left lower, 600 spot/cm²; right upper, 1,000 spot/cm²; right lower, 1,500 spot/cm²; upper center, 2,000 spot/cm²). (B) Hair regrowth was found in areas irradiated using high density energy, irrespective of energy level. (C) Hair regrowth was more distinct in frequently irradiated mice and on the right sides of the backs treated with high-density irradiation.

or administration of any medication was not permitted during the course of the investigation.

Evaluation Criteria: A photograph and phototrichogram were taken of each participant before treatment and 1 month after the last treatment. Biopsies were taken before treatment and 1 month after the last treatment from five volunteers who agreed to provide tissue samples. In 16 of the participants, long-term follow-up examinations were performed 4 months after the final treatment using a phototrichogram to evaluate hair density.

Clinical photography: An evaluation of the degree of hair loss was performed before each treatment session and 1 month after the final treatment. Five standard digital photographs were taken (EOS 40D, 6.0 megapixels, Canon, Tokyo, Japan) before each treatment session.

Phototrichogram system: To obtain a more objective assessment of hair regrowth, a phototrichogram system (Folliscope, Lead-M Corporation, Seoul, Korea) was used in the computer-aided evaluations of hair thickness, density, and growth rate. The phototrichograms were taken at the same location on the parietal scalp before each treatment session and 1 month after the final session.

Histopathologic studies: To evaluate histopathologic changes, 4-mm punch biopsies of the scalp were obtained from five participants under local anesthesia before treatment and 1 month after the last treatment. The tissue samples were prepared for light microscopy examination using 10% formalin fixation. Paraffin-embedded 3- μ m-thick tissue sections were processed using hematoxylin and eosin (H&E) staining.

Molecular studies: Several molecular signals known to be associated with the hair cycle were analyzed, including semi-quantitative reverse transcriptase polymerase chain reaction (RT-PCR) with Wnt signal probes before the laser irradiation and 3 and 24 hours after the fractional photothermolysis laser irradiation.

Results

We observed hair stimulation caused by irradiation with the 1,550-nm fractional erbium-glass laser in the animal study, which was related to changes in the hair cycle. The hair stimulation effects were dependent on the energy levels, densities, and irradiation intervals. The first animal study showed that irradiation with high-density energy can induce hair regrowth of telogen-phase mouse hair. Hair regrowth was found in areas irradiated using high-density energy irrespective of the specific energy level (Figure 1B). The second animal study showed that hair regrowth was dependent on the irradiation interval and the energy density. Hair regrowth was more distinct in frequently irradiated mice and on the right sides of the backs, which had been exposed to high-density irradiation (Figure 1C). Low energy with high density at a frequent irradiation interval of at least every 2 weeks induced considerable hair stimulation. Histologic findings revealed the anagen conversion of hair, as shown in Figure 2. Fractional laser irradiation can promote anagen hair growth, promoting change from the telogen phase to the anagen phase. Molecular studies showed changes in molecular signals and cytokines associated with the hair cycle; laser irradiation increased Wnt 5a and β -catenin signal levels (Figure 3). The changes in the Wnt signal and the expression of β -catenin appear to be related to hair growth stimulated by fractional laser irradiation.

Based on the results of the animal study, we expanded our investigation of laser-assisted hair growth in humans. In the human pilot study for MPHL, clinical improvement was observed in most of the participants (Figure 4). Increases in hair density (Figures 5A and B) and growth rate improvements (Figures 5C and D) were observed after fractional photothermolysis laser treatment, although no significant changes in hair caliber were observed. At a 4-month follow-up after the final treatment, hair density had decreased from 1 month after treatment to baseline levels.

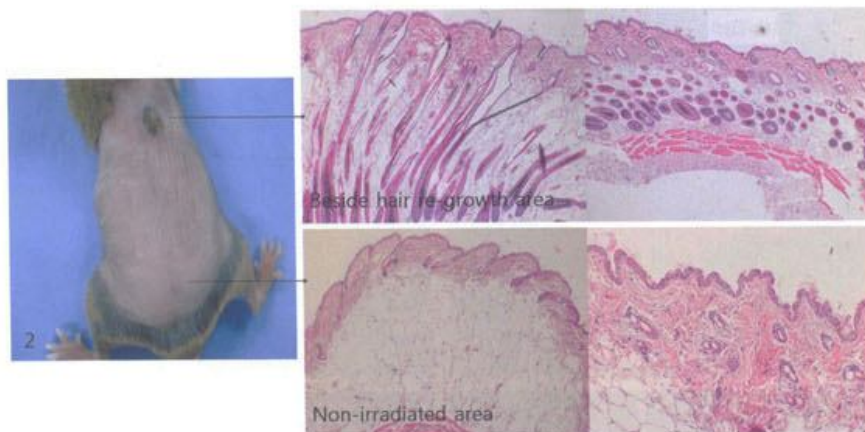


Figure 2. Histologic findings revealed conversion of the telogen phase to the anagen phase.

Histologic findings revealed an increase in the number of anagen hair follicles and the anagen:telogen ratio on the mid and superficial dermis, as shown in Figure 6, although focal fibrotic changes around the hair follicles were observed on the superficial dermis. Most newly formed anagen hair follicles presented as vellus hair and were unable to form a complete pilosebaceous unit composed of a sebaceous gland and hair follicle (Figure 6).

Semi-quantitative RT-PCR studies with Wnt-related primers showed induction of the Wnt10a signal 24

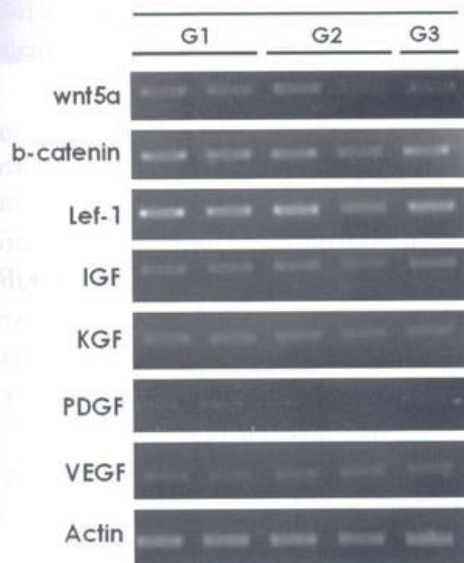


Figure 3. Molecular studies showed changes in molecular signals and cytokines associated with hair cycles. Wnt 5a and β -catenin signals were increased using laser irradiation.

hours after the fractional photothermolysis laser irradiation (Figure 7).

Adverse Effects

Breakage of the hair shaft was occasionally observed after irradiation, the extent of which was associated with energy, density, and the manual skill of the operator, especially at the high energy settings. Microscopic analysis using scanning electron microscopy showed blunt damage to the hair cuticles and cortex (Figure 8). This was most noticeable when high-energy, low-density laser irradiation was used. Seventeen participants complained about transient shedding for 1 to 2 weeks after irradiation. This phenomenon might be related to damage to the hair shaft and the effects of telogen to anagen conversion. Pain was observed during treatment in most participants. Side effects such as mild post-treatment erythema ($n = 11$), pruritus ($n = 4$), dryness ($n = 10$), and dandruff ($n = 7$) were also observed. All of these complications resolved within 1 week after irradiation.

Discussion

Androgenetic alopecia is defined as hereditary thinning of the hair induced by androgens in genetically susceptible men and women. It is also known as MPHL in men and female-pattern hair loss in women. The pathophysiology of androgenetic

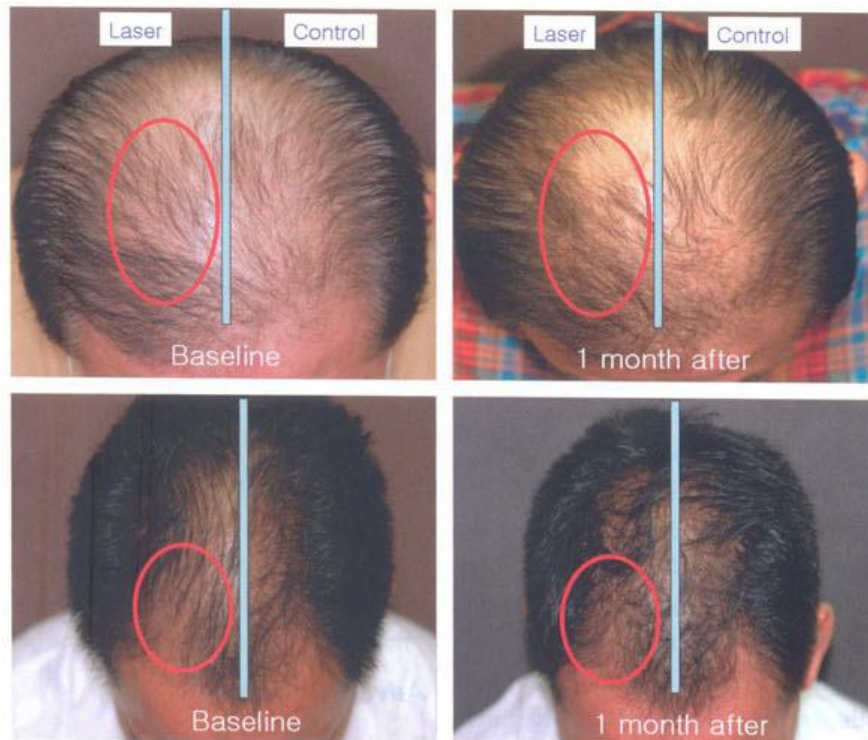

Figure 4. In the human pilot study for the treatment of male pattern hair loss, clinical improvement was observed in most of the participants.

alopecia is not fully understood. It is thought that progressive diminutions of the hair shaft diameter and length may be due to the presence of systemic androgens. Miniaturization of follicles, shorter anagen, longer telogen, and longer latency are observed in men with MPHL. Although vellus hairs in the pubic area, axilla, male chest, and face convert to terminal hairs without androgens, terminal hairs on the scalp change to vellus hairs because of the site-specific action of androgens.⁹

Treatment goals in people with androgenetic alopecia include greater hair coverage of the scalp and slowing of further hair thinning. Effective medications, including minoxidil, finasteride (competitive inhibitors of type II 5- α reductase), and dutasteride (a competitive inhibitor of type I and II 5- α reductase), are available to treat MPHL,¹ with minoxidil and finasteride remaining the first-line treatments. Hair transplantation surgery is another common treatment option for patients who do not respond to the medical therapies. However, conventional medical treatments

result in less satisfactory outcomes for some people. Furthermore, hair transplantation has limitations in that it is invasive, expensive, and not ideal for the early stages of hair loss. There is interest in the potential roles of laser and light treatments for male and female hair loss to bypass some of the limitations of medical treatments.²

Only a few clinical trials that have investigated the efficacy of LLLT for hair growth have been published in peer-reviewed journals. Observations from 50 years ago indicated that, in mice, rabbits, and humans,¹⁰⁻¹² some new hair follicles develop after wounding. Ito and colleagues¹³ found that cells that made up newly formed hair follicles were derived from the interfollicular epidermis and not from existing hair bulges. If proper wounding can initiate hair growth, laser wounding for the treatment of alopecia could be possible.

Several laser types are available for proper wounding and subsequent hair growth. Several cases and




Figure 5. Improvements in hair density (A, B) and growth rates (C, D) were observed after fractional photothermolysis laser treatment. At 4-month follow-up after the final treatment, hair density had decreased to baseline levels from 1 month after treatment.

studies on the treatment of alopecia areata have involved the use of 308-nm excimer laser irradiation,^{14,15} 904-nm pulsed infrared lasers, and 810-nm diode laser irradiation.^{7,16} In this study, we used a fractional 1,550-nm laser to induce microcoagulative wounds in the dermis. Penetration depth and wound size can be easily regulated using a fractional near-infrared laser, allowing for the formation of wounds without bleeding.¹⁷ Despite the energy loss caused by reflection off the hair surface, a fractional laser beam can penetrate the hairy scalp more efficiently than can other laser systems.

In this study, we have demonstrated that hair growth and modulation of the hair cycle in C3H mice are possible. The study involved the use of fractional photothermolysis laser treatment on the shaved back skin of eight 7-week-old C3H/HeN mice whose hair was in the telogen stage. On the basis of the C3H animal study, we applied the fractional photothermolysis laser to 20 human participants with MPHL. The second study was designed to evaluate the effects of fractional photothermolysis laser in the treatment of MPHL in humans.

Suggested mechanisms for inducing hair growth using fractional lasers include greater blood flow; induction of cytokines and growth factors that are associated with hair biology, such as platelet-derived growth factor, keratinocyte growth factor, insulin-like growth factor, and fibroblast growth factor; and direct stem cell, bulge cell, or dermal papilla cell stimulation. Fractional lasers, which are widely used for resurfacing and dermal remodeling, can generate predictable thermal damage or fractional photothermolysis. These induce collagen regeneration and heat shock proteins, which have been demonstrated to play a role in the expression of various growth factors, including vascular endothelial growth factor (VEGF). VEGF has been found to induce neoangiogenesis, which promotes hair and adipocyte growth. In the animal study, we demonstrated possible hair growth and modulation of the hair cycle in the C3H mice using a fractional photothermolysis laser. We discovered that changing the

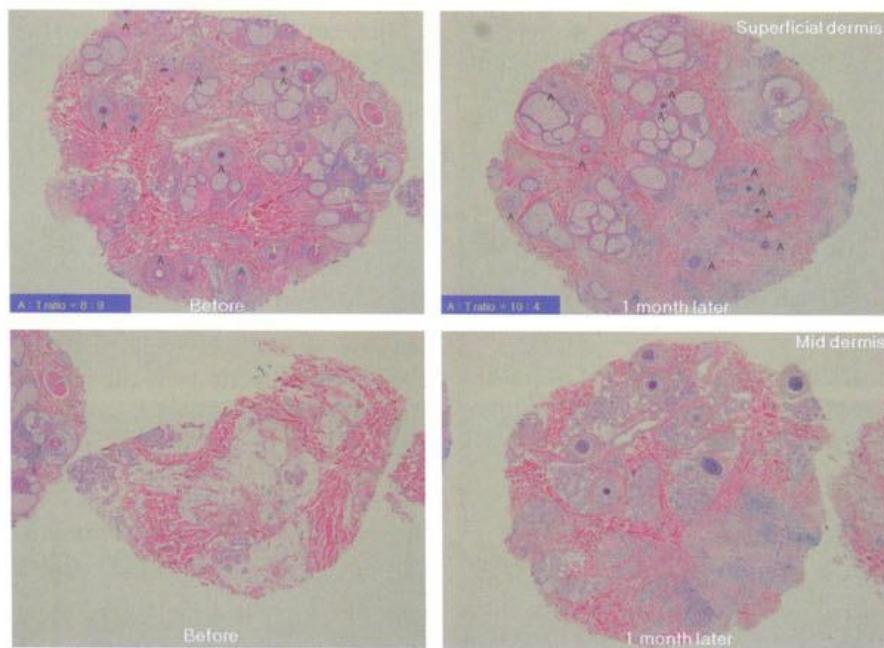


Figure 6. Histologic findings revealed that anagen hair follicles and the anagen:telogen ratio increased in the superficial and mid-dermis. They also showed focal fibrotic changes around the hair follicles at the mid-dermis after irradiation.

Wnt signal and expression of β -catenin might be related to hair growth induced using fractional laser irradiation. One of the earliest molecular pathways that positively regulate hair follicle initiation is the Wnt/ β -catenin pathway. β -catenin is the downstream mediator of Wnt signaling, and Wnt/ β -catenin/Lef-1 signaling plays an important role in hair shaft formation.¹⁸ Many crucial Wnt molecules, such as

Wnt5a, 10a, and 10b, are expressed at specific morphogenetic epidermal placode areas in the murine hair follicle model.¹⁹ In our human pilot study, mRNA of unique Wnt10a was highly expressed 24 hours after fractional photothermolysis laser irradiation. As reported in the mouse model, Wnt 10a is mainly expressed in the epithelial bulge area during anagen onset and could be expected to initiate β -catenin activation of the dermal papilla. Scalp tissue biopsies were taken 24 hours after irradiation, illustrating that Wnt signals, such as Wnt10a, were only elevated in the mRNA at the tissue level. Other wound-related Wnt4, bulge-related Wnt3a, papilla-producing Wnt5a, and tissue β -catenin expressions were not changed at the tissue sampling point. If additional tissue samples had been available, it might have been possible to identify additional anagen-related Wnt molecules that play a role in laser-induced hair growth.

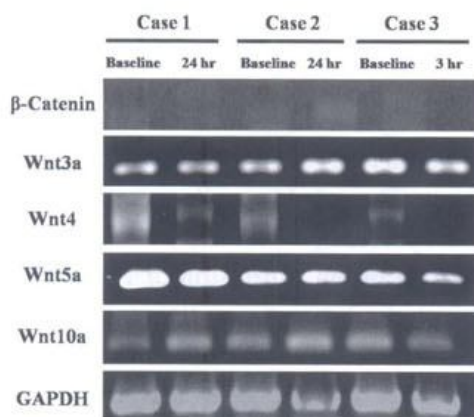


Figure 7. Semiquantitative reverse transcriptase polymerase chain reaction studies with Wnt-related primers showed induction of the Wnt10a signal 24 hours after fractional photothermolysis laser irradiation.

Animal studies and human trials suggest the usefulness of the fractional 1,550-nm laser for the treatment of alopecia. Fractional laser treatment may enhance hair density, growth rate, and the




Figure 8. Breakage of the hair shaft was observed after irradiation and was associated with energy, density, and the manual skills of the clinician, especially at the high-energy setting. Microscopic analysis using scanning electron microscopy showed blunt damage to the hair cuticle and cortex.

anagen:togen ratio but has no effect on hair thickness. Proper energy levels and densities are necessary for the effective stimulation of hair growth. Laser treatments that are too frequent or use excessively high energy levels may induce excessive fibrotic changes after irradiation, further exacerbating the alopecia. A high-energy protocol could increase the incidence of hair shaft breakage by damaging the hair cuticle and cortex. Frequent treatment (>2 times/week) could induce fibrotic changes around the hair follicle. Therefore, a low-energy, high-density protocol for treatments at a 2-week interval was thought to be the most suitable protocol for the treatment of MPHIL. Clinical data showed that hair density decreased 4 months after

discontinuing the treatment, so continuous treatment is needed to maintain the benefits of laser treatment.

Although scalp samples showed a greater number of anagen hair follicles in the superficial and mid-dermis 1 month after the last treatment, most anagen hair follicles did not contain sebaceous glands. This incomplete pilosebaceous unit composed of only a hair follicle may later induce inflammation. Because the newly formed anagen hair was vellus hair 1 month after treatment, follow-up biopsies were needed to evaluate the long-term effects of the laser treatment. Further studies, including controlled prospective human studies, investigating the exact mechanisms must be conducted to confirm the

effectiveness of the fractional laser. Additional studies could confirm the most suitable parameters, including energy, density, and treatment intervals, as well as the best applicators for energy delivery to the hairy scalp.

Fractional lasers appear to be effective for inducing hair regrowth. We speculate that proper wounding through laser or similar irritations causes regrowth of hair follicles. Other forms of irritation such as squaric acid dibutylester also can produce improvement of MPHL and alopecia areata in some settings. For this reason, well-controlled studies are required for physicians to be able to use fractional lasers as a therapeutic tool in the treatment of MPHL. Additionally, the efficacy, adverse effects, safety, and long-term benefits of lasers for the treatment of hair loss need to be evaluated. Fractional laser treatment may provide supportive care for persons with MPHL, but it cannot replace current treatment methods. This technique could potentially be used in combination with conventional treatments; for example, a fractional laser combined with topical agents or with anti-androgen agents might yield improved outcomes.

This study is significant because we verified through animal testing that fractional laser treatment had an effect on hair stimulation. The application of fractional laser treatment to men with receding hair validated these hair stimulation effects, although the mechanism of action was not clear, and there are limits to its application as a clinical treatment because of the side effects. Application of fractional laser for alopecia is not yet a standard treatment, and further studies are needed to confirm its mechanism and role. It is vital to evaluate the stability and effects of laser therapy through additional testing and long-term tracking and observation of participants. These future studies could elucidate the mechanism of action based on pre- and postlaser treatment comparisons of cytokines, neuropeptides, and other small cell-signaling protein molecules. Also, we are preparing a follow-up split scalp study with fractional laser in a set of participants with

MPHL who are being treated for at least 1 year with finasteride to assess the synergistic effect of these two hair stimulation processes.

Acknowledgments This work was supported in part by Grant C-A9-305-1 from the Samsung Biomedical Research Institute.

References

1. Khandpur S, Suman M, Reddy BS. Comparative efficacy of various treatment regimens for androgenetic alopecia in men. *J Dermatol* 2002;29:489-98.
2. Avram MR, Leonard RT Jr, Epstein ES, et al. The current role of laser/light sources in the treatment of male and female pattern hair loss. *J Cosmet Laser Ther* 2007;9:27-8.
3. Satino JL, Markou M. Hair regrowth and increased hair tensile strength using the HairMax LaserComb for low-level laser therapy. *Int J Cosmet Surg Aesthet Dermatol* 2003;5:113-7.
4. Bouzari N, Firooz AR. Lasers may induce terminal hair growth. *Dermatol Surg* 2006;32:460.
5. Kontoes P, Vlachos S, Konstantinos M, et al. Hair induction after laser-assisted hair removal and its treatment. *J Am Acad Dermatol* 2006;54:64-7.
6. Alajlan A, Shapiro J, Rivers JK, et al. Paradoxical hypertrichosis after laser epilation. *J Am Acad Dermatol* 2005;53:85-8.
7. Bernstein EF. Hair growth induced by diode laser treatment. *Dermatol Surg* 2005;31:584-6.
8. Levy V, Lindon C, Zheng Y, et al. Epidermal stem cells arise from the hair follicle after wounding. *FASEB J* 2007;21:1358-66.
9. Paus R, Olsen EA, Messenger AG. Hair growth disorder. In: Wolff K, Goldsmith LA, Katz SI, Gilchrist BA, Paller AS, Leffell DJ, editors. *Fitzpatrick's dermatology in general medicine*. 7th ed. New York: McGraw-Hill; 2008. p. 753-77.
10. Kligman AM, Strauss JS. The formation of vellus hair follicles from human adult epidermis. *J Invest Dermatol* 1956;27:19-23.
11. Billingham RE, Russell PS. Incomplete wound contracture and the phenomenon of hair neogenesis in rabbits' skin. *Nature* 1956;177:791-2.
12. Breedis C. Regeneration of hair follicles and sebaceous glands from the epithelium of scars in the rabbit. *Cancer Res* 1954;14:575-9.
13. Ito M, Yang Z, Andl T, et al. Wnt-dependent *de novo* hair follicle regeneration in adult mouse skin after wounding. *Nature* 2007;447:316-20.
14. Nawaf AM. 308-nm excimer laser for the treatment of alopecia areata. *Dermatol Surg* 2007;33:1483-7.
15. Gundogan C, Greve B, Raulin C. Treatment of alopecia areata with the 308-nm xenon chloride excimer laser: case report of two successful treatments with the excimer laser. *Lasers Surg Med* 2004;34:86-90.

16. Waiz M, Saleh AZ, Hayani R, Jubory SO. Use of the pulsed infrared diode laser (904 nm) in the treatment of alopecia areata. *J Cosmet Laser Ther* 2006;8:27-30.
17. Cho SB, Lee JH, Choi MJ, et al. Efficacy of the fractional photothermolysis system with dynamic operating mode on acne scars and enlarged facial pores. *Dermatol Surg* 2009;35:108-14.
18. Cotsarelis G, Botchkarev V. Biology of hair follicles. In: Wolff K, Goldsmith LA, Katz SI, Gilchrist BA, Paller AS, Leffell DJ, editors. *Fitzpatrick's dermatology in general medicine*. 7th ed. New York: McGraw-Hill; 2008. p. 739-48.
19. Reddy S, Andl T, Bagasra A, et al. Characterization of Wnt gene expression in developing and postnatal hair follicles

and identification of Wnt5a as a target of Sonic hedgehog in hair follicle morphogenesis. *Mech Dev* 2001;107:69-82.

Address correspondence and reprint requests to: Beom Joon Kim, MD, PhD, Department of Dermatology, Chung-Ang University Yongsan Hospital, 65-207 Hangangro 3-ka, Yongsan-gu, Seoul 140-757, South Korea, or e-mail: beomjoon@unitel.co.kr