

# Objective and Quantitative Improvement of Rosacea-Associated Erythema After Intense Pulsed Light Treatment

KENNETH A. MARK, MD, ROSE MARIE SPARACIO, MS, MBA, AUDRA VOIGT, BS, KENNETH MARENUS, PHD, AND DEBORAH S. SARNOFF, MD

Department of Dermatology, New York University School of Medicine, New York, New York

**BACKGROUND.** Despite the widespread and quite successful use of various lasers and light sources to treat facial erythema, the literature contains little, if any, objective and quantitative improvement. In addition, very few studies specifically address rosacea-associated erythema.

**OBJECTIVE.** To assess quantitatively the degree of improvement in patients with rosacea after intense pulsed light treatment. The three main parameters that were objectively measured were blood flow, telangiectasia, and erythema.

**METHODS.** Four patients with rosacea-associated erythema and telangiectasia were treated five times at 3-week intervals with the Photoderm VL (Lumenis, Needham, MA). The 515-nm filter, a single pulse duration of 3 ms, and various fluences were

used. Blood flow was measured by the scanning laser Doppler. Close-up photography ensured reproducibility and enabled quantification of telangiectasia and erythema by subsequent computer image analysis. Measurements were taken at baseline and at 1 month after the last treatment.

**RESULTS.** The scanning laser Doppler demonstrated a 30% decrease in blood flow ( $P < 0.05$ ). A 29% decrease in actual area of the cheek occupied by telangiectasia was noted ( $P < 0.05$ ). A 21% decrease in the intensity of erythema was noted ( $P < 0.05$ ). **CONCLUSION.** As demonstrated by truly objective and quantitative means, intense pulsed light is effective for reducing rosacea-associated blood flow, telangiectasia, and erythema.

K. A. MARK, MD, R. M. SPARACIO, MS, MBA, A. VOIGT, BS, K. MARENUS, PHD, AND D. S. SARNOFF, MD HAVE INDICATED NO SIGNIFICANT INTEREST WITH COMMERCIAL SUPPORTERS.

**SEVERAL LASERS and light** sources have been shown to be excellent for the treatment of facial erythema and/or telangiectasias. However, other than preoperative and postoperative photographs and their inherently subjective interpretation, the literature contains little if any objective and quantitative data. In addition, very few studies specifically address rosacea-associated erythema.

In a large series, Angermeler<sup>1</sup> reported 75% to 100% clearance of facial vascular lesions with intense pulsed light. One hundred seventy-four patients were treated between one and four times. Arndt<sup>2</sup> demonstrated effective use of the Argon laser for rosacea. Results included "fair, good, and excellent." Lowe et al. obtained a "good to excellent" response in 24 of 27 patients who had rosacea-associated telangiectasia and erythema and were treated with the flash-lamp pumped dye laser.

Several other authors have reported on various other laser systems for facial telangiectasia. Results have included satisfactory, good, significant improve

ment, and successful fading.<sup>4-11</sup> Even if these studies included photographs, the evaluations were ultimately based on the subjective interpretation of the physician, patient, or both.

## Methods

Via the use of biophysical instrumentation, the degree of improvement in patients with rosacea, after intense pulsed light treatment, was objectively quantified. The three main parameters that were measured were blood flow, telangiectasia, and erythema.

## Patients and Treatment

Four patients with rosacea-associated erythema and telangiectasia received five treatments every 3 weeks with the Photoderm VL (Lumenis, Needham, MA). A 515-nm filter, a single pulse duration of 3 ins, and fluences between 22 and 25J/cm<sup>2</sup> were used. All patients were females, aged 43 to 55 years old. The mean number of pulses received (per check, per treatment) was between 8 and 12. One of the four patients had papules and pustules (Table 1).

Address correspondence and reprint requests to: Kenneth A. Mark, MD, 200 Pantigo Place, Suite D, East Hampton, NY 11937.

**Table 1. Patient Demographics and Treatment Parameters**

Patient	Age (Years)	Gender	Mean Fluence (J/cm <sup>2</sup> )	Mean Number of Pulses	Papules and Pustules
1	43	Female	24.2	8	
2	52	Female	23.1	10.4	Yes
3	55	Female	23	11.4	No
4	49	Female	22.8	11.8	No No

All patients were nonpregnant, had no systemic illnesses, and were not using or taking any rosacea medications for at least 1 month before the study. All patients used the same cleanser and sunscreen daily. Measurements and photographs were taken at baseline and at 1 month after the last treatment. The right and left cheeks were treated, but data for this study were collected from the right cheek. All patients signed informed consent after consultation.

The patients in the study were required to keep the time of their appointment, for measurement, the same from visit to visit. Before testing, they equilibrated in an environmentally controlled room at 70° F and 40% relative humidity for one-half hour.

#### Blood Flow

Cutaneous blood flow on the right cheek was measured via the scanning laser Doppler Imager (Moor Instruments, UK). The optical scanner is comprised of two mirrors, which guide a low-power He-Ne laser beam to the skin. Mirrors move the laser beam sequentially over the tissue. The beam illuminates the tissue to a depth of a few hundred micrometers. At each point of interaction with the moving blood cells, the light becomes spectrally broadened because of the Doppler effect. The intensity of back scatter of light is converted into an electrical signal and processed to form an output value proportional to the perfusion, defined as the product of the blood cell speed and concentration.<sup>12</sup> The decrease in blood flow was equal to the value obtained after treatments subtracted from the baseline measurements.

#### Clinical Photography

Close-up photography of the right and left cheeks was performed. The patients' heads were placed in a head rest to ensure reproducibility of positioning. The patients' cheeks were blotted with absorbing paper to avoid reflection from skin surface oils. The camera was positioned 2 feet from the patients at an F stop of 32 with a cross-polarized lens. The photography

documented excellent clinical photos but also enabled subsequent computer-generated image analysis to quantify telangiectasia and erythema.

#### Telangiectasia

Telangiectasia was measured as the area of a fixed and reproducible part of the treated cheek that contained superficial vessels that were detected by the image analyzer.

#### Erythema

Color was broken down into red, green, and blue components by the computer. The gray value of the red channel was quantified on a scale of 0 to 255. Zero represented black, and 255 represented maximum brightness.

#### Statistics

The Excel data analysis package was used to assess the statistical significance of the data employing the two-sample z-test. This form of the z-test examines whether two samples' means are distinct. A paired z-test is appropriate whenever there is a natural pairing of observations in the samples and if any of the following three conditions are present: the data are not normal, the n is less than 16, or the sample variances are not equal. In this study, the z-test was chosen because of the small n. Each time point within the group was compared to pretreatment (baseline).

#### Subjective Analysis

Patients were asked to rate their degree of improvement on a scale of 0 to 4, the psychosocial impact of their improvement on a scale of 0 to 10, and to qualify it from a choice of adjectives, such as somewhat, good, or great. Clinically, Dr. Mark rated the patients' overall improvement on a scale of 0 to 4.

#### Results

The scanning laser Doppler demonstrated an average 30% decrease in blood flow ( $P < 0.05$ ; Table 2). Figure 1 illustrates the before and after scanning laser Doppler images of blood flow for patient 2. The red, orange, and yellow areas indicate maximal blood flow. A 29% decrease in the actual area occupied by telangiectasia was noted ( $P < 0.05$ ; Table 3). A 21% decrease in the intensity of erythema was noted ( $P < 0.05$ ; Table 4). Figure 2 depicts before and after clinical photos of patient 4.

**Table 2. Blood Flow as Measured by Scanning Laser Doppler**

Average Baseline	Average After Treatment	Percentage Reduction	P Value
160.6	112.4	30.03	<0.05

Subjectively, one of four patients reported "great" improvement, whereas three of four reported somewhat improvement. Table 5 shows the patients' ratings of their improvement versus Dr. Mark's evaluations and the patients' degree of psychosocial improvement.

Several months after the last IPL treatment and measurement, no repeat objective measurements were performed on any of the patients. However, on clinical follow-up visits, the improvement was subjectively noted to last at least 6 months in all four of the patients.

### Discussion

This is one of the few studies that has ever examined the use of lasers/light sources for the treatment of rosacea-associated erythema. It is only one of two studies documenting the use of intense pulsed light treatment for rosacea. This is the only study with objective and quantitative data for the improvement of rosacea-associated blood flow, telangiectasia, and erythema.

The use of the scanning laser Doppler, with regards to laser treatment or rosacea, is not completely novel.

**Table 3. Telangiectasia as Measured by Area**

Average Baseline Value	Average After Treatment	Percentage Reduction	P
2.54	1.80	29.11	< 0.05

**Table 4. Erythema as Measured by Grey Value, on a Scale of 0 to 255**

Average Baseline Value	Average After Treatment	Percentage Reduction	P
166.48	132.35	20.50	< 0.05

Nelson et al. 13 recently described the use of laser Doppler flowmetry combined with optical coherence tomography to measure blood flow in a port-wine stain after laser treatment. Over 10 years ago, rosacea patients were found to have a threefold to fourfold increased blood flow, by laser Doppler flowmetry, versus control patients. 14 Wittenberg et al. 15 recently used the laser Doppler to measure the decrease in blood flow in hypertrophic scars treated with the pulsed-dye laser but found no difference compared with the control group.

The strength of this study was the purely objective and quantitative nature of the data. Even before and after clinical photographs that are performed extremely well and are 100% reproducible are subject to

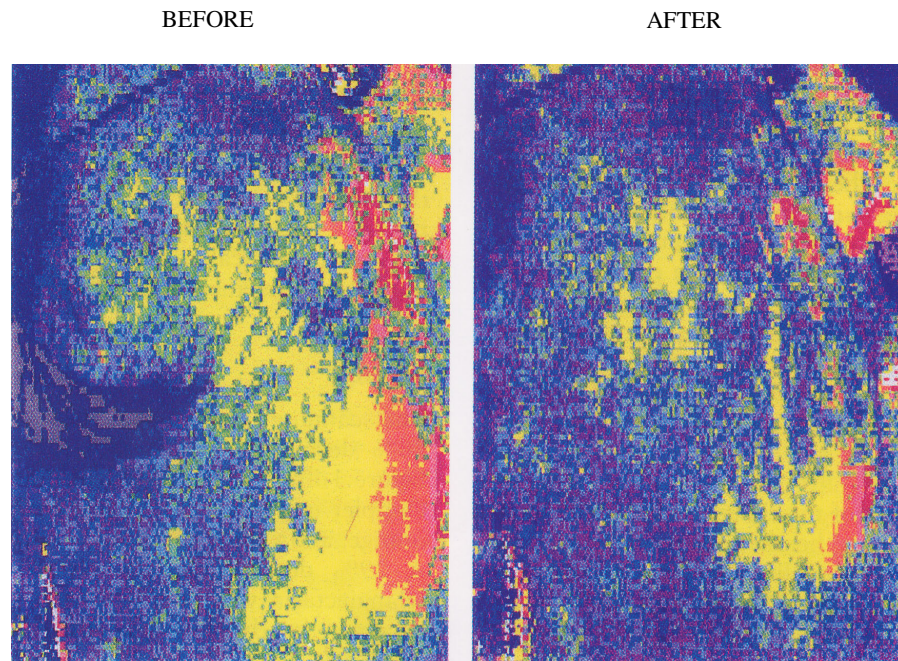


Figure 1. Scanning laser Doppler images of blood flow before and after treatment.

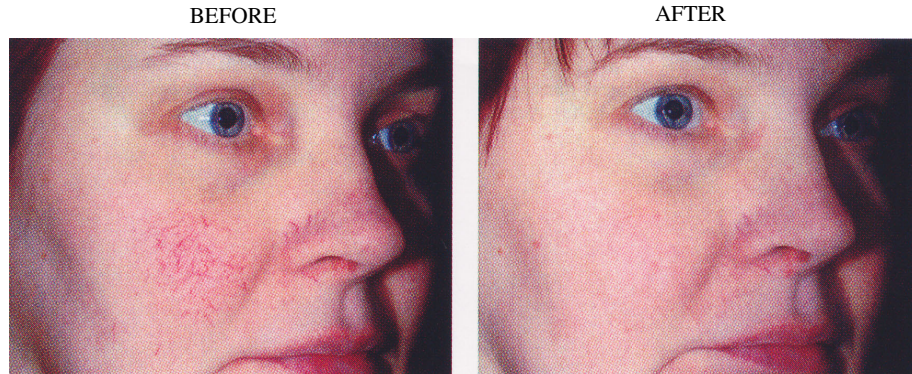


Figure 2. Clinical photography of patient 4 before and after treatment.

Table 5. Subjective Analysis

Patient	Patients' Rating of Improvement (0-4)	Dr Mark's Rating of Improvement (0-4)	Patients' Rating of Psychosocial Improvement
	3	3	8
	2.5	3	8
	3.5	4	9.5
	4	4	7.5

the inherently subjective nature of additional human evaluation.

The subjective variability was highlighted in the fact that only two of the four patients' ratings matched Dr. Mark's. In addition, despite the fact that only one of the four patients rated her improvement as great, three of the four rated their improvement a 3 or better on a scale of 0 to 4 (3, 3.5, and 4). Furthermore, the psychosocial impact of the improvement was at least 80% improved in three of the four, yet again, only one of the four rated the improvement as great (Table 5).

Although the results may appear modest, it should be noted that when these data were presented at the American Society for Dermatologic Surgery Annual Meeting in Dallas, the gross majority of the audience appreciated a 75% improvement. Indeed, this would represent 75% improvement toward what we are accustomed to being normal, that is, 75% apparent clearing of erythema. In terms of the objective data, however, the results are more modest because the patients' disease severity was relatively so severe.

An obvious limitation of this study was the small number of four patients. However, this was a pilot study, unique in its objective and quantitative nature. It is noteworthy that from patient to patient the results were relatively consistent; however, the individual

variation in response to treatment warrants a larger study in the future.

## Conclusion

This study objectively and quantitatively supported the use of intense pulsed light to reduce the blood flow, telangiectasia, and erythema associated with rosacea. It also highlighted the variability in results that can occur from patient and from physician to patient when left to purely subjective interpretation.

## References

1. Angermeier MC. Treatment of facial vascular telangiectasia with intense pulsed light. *J Cutan Laser Ther* 1999;1:95-100.
2. Arndt KA. Argon laser therapy of small cutaneous vascular lesions. *Arch* 1982; 118:220-4.
3. Lowe NJ, Behr KL, Fitzpatrick R, Goldman M, Ruiz-Esparza J. Flash lamp pumped dye laser for rosacea -associated telangiectasia and erythema. *J Oncol* 1991;17:522-5.
4. Dicken CH. Argon laser treatment of the red nose. *J Oncol* 1990;16:33-6.
5. Apfelberg DB. Argon-pumped tunable dye laser. *Ann Plast* 1994;32:394-400.
6. West TB, Alster TS. Comparison of the long-pulse dye (590/595 nm) and KTP (532 nm) lasers in the treatment of facial and leg telangiectasias. 1998;24:221-6.
7. Waner M, Dinehart SM, Wilson MB, Flock ST. A comparison of copper vapor and flashlamp pumped dye lasers in the treatment of facial telangiectasia. *J Oncol* 1993;19:992-8.
8. Orenstein A, Nelson JS. Treatment of facial vascular lesions with a 100mu spot 577nm pulsed continuous wave dye laser. *Ann Plast* 1989;23:310-6.
9. Scheepers JH, Quaba AA. Clinical experience in the treatment of the "red nose" using flashlamp-pumped pulsed dye laser (585nm). *Aesthetic Plast* 1994;18:57-60.
10. Ruiz-Esparza J, Goldman MP, Fitzpatrick RE, Lowe NJ, Behr KL. Flash lamp-pumped dye laser treatment of telangiectasia. *J Oncol* 1993;19:1000-3.
11. Broska P, Martinho E, Goodman MM. Comparison of the argon tunable dye laser with the flashlamp pulsed dye laser in treatment of facial telangiectasia. *J Oncol* 1990;749-53.
12. Bernadi L, Berardesca E. *Bioengineering of the Skin: Methods and Instrumentation*. Florida: CRC Press 1995;13-28.

13. Nelson JS, Kelly KM, Zhao Y, Zhongping C. Imaging blood flow in human port-wine stain in situ and in real time using optical Doppler tomography. *Arch Dermatol* 2001;137:741-4.
14. Sibenge S, Gawkrödger Dj. Rosacea: a study of clinical patterns, blood flow, and the role of *Demodex folliculorum*. *J Am Acad Dermatol* 1992;26:590-3.
15. Wittenberg GP, Fabian BG, Bogomilsky JL, et al. Prospective, single-blind, randomized, controlled study to assess the efficacy of the 585-nm flashlamp-pumped pulsed-dye laser and silicone gel sheeting in hypertrophic scar treatment. *Arch Dermatol* 1999;135:1049-55.