



Case Report:

Nd: YAG LASER for treating venous lake occurrences.

Flávia Pereira Reginatto, dermatologist
Passo Fundo, RS, Brazil.

White paper case report described by dermatologist Flavia Reginatto, from Passo Fundo, Rio Grande do Sul (RS), Brazil. Dr. Reginatto used the ETHEREA-MX®, platform with the LongPulse® handpiece.

Tratamento:

- ▶ **Venous lake:** varicose veins, that is, vascular ectasias (dilations) that occur on the lips. They are asymptomatic, but cause great aesthetic discomfort.
- ▶ LongPulse®: Nd: YAG LASER is the most recommended wavelength for transdermal treatment of limb and face vascular lesions.
- ▶ The type of LASER used in this work is absorbed by hemoglobin, leading to a process of vessel coagulation with a consequent excision of the lesion.
- ▶ The procedure causes little pain and/or discomfort. The number of sessions for an ideal and definitive outcome may vary from 1 to 5, carried out monthly.
- ▶ In the given case, the therapeutic choice for laser proved to be effective and safer than other options to treat hemangioma in the oral cavity (sclerotherapy and surgery), commonly used and described in literature.
- ▶ 1 session was performed, LongPulse®, 6 mm spot, 90 J/cm², 20 ms.

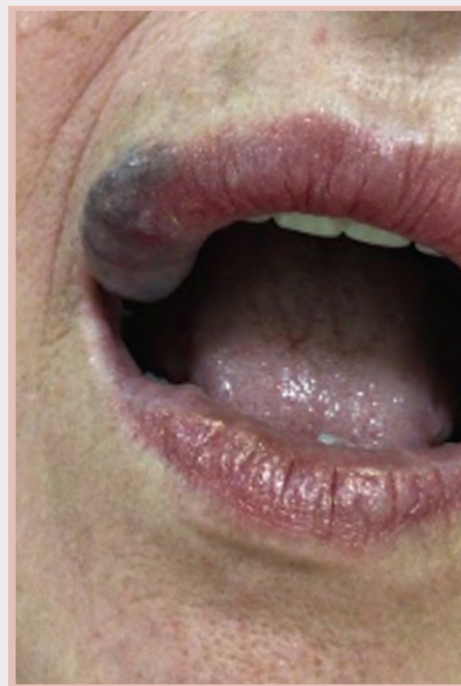

Image A: Pre-treatment.

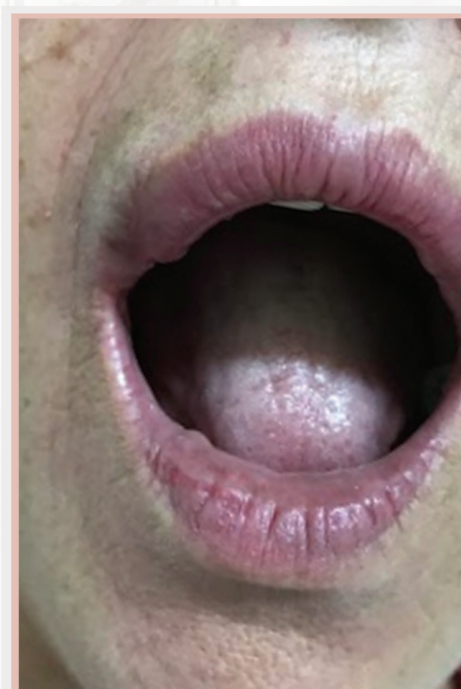
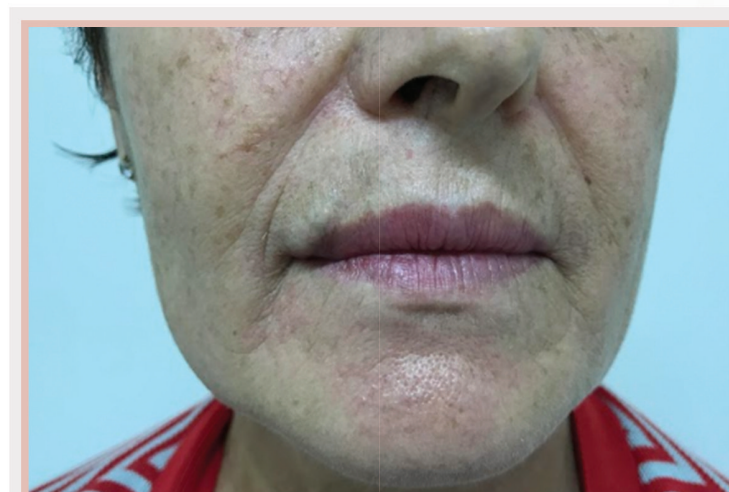


Image B: After one treatment session.



After-treatment photo.